CATARACTS

BY: DR. MILLICENT KARIUKI-WANYOIKE

EYE

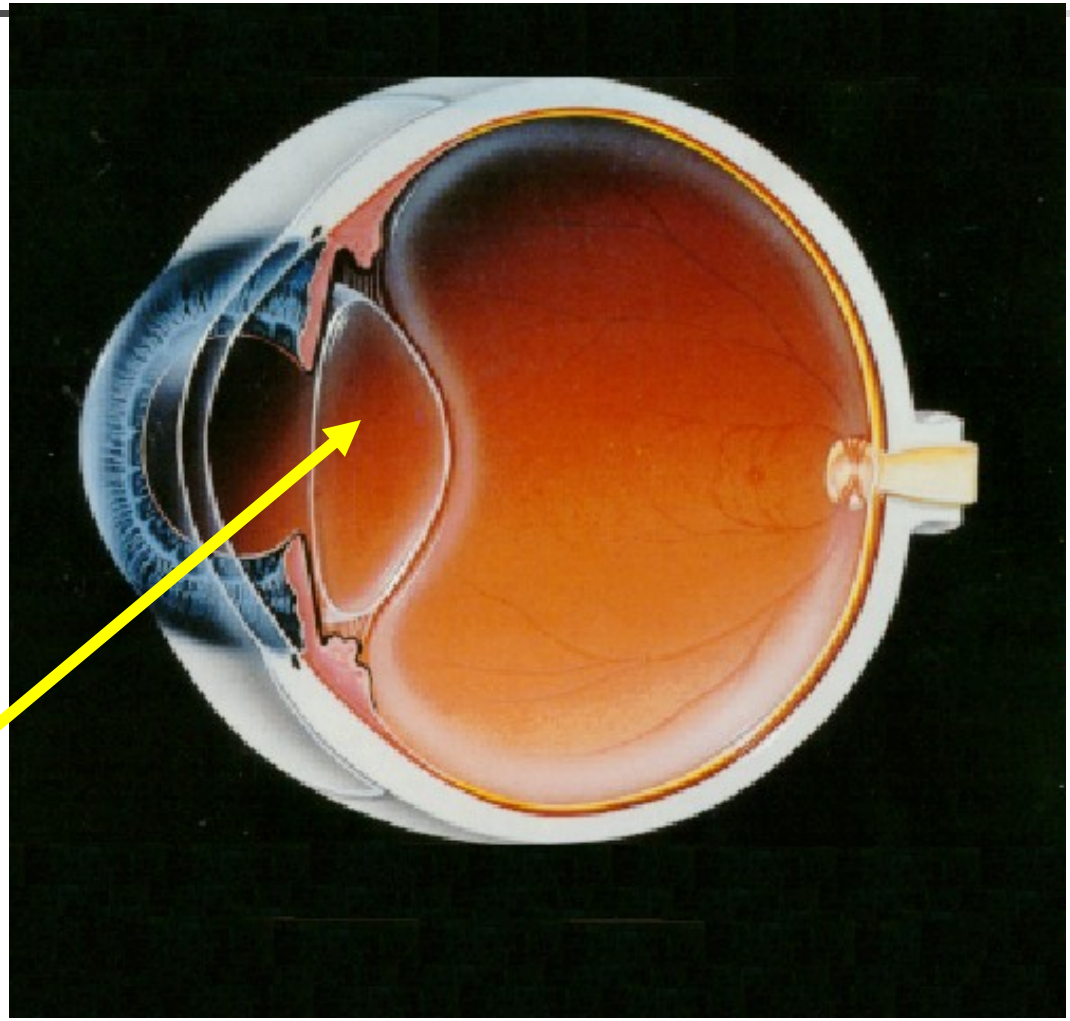

Lens

INTRODUCTION

- *The lens is a biconvex and perfectly transparent organ, held in position behind the iris by the suspensory ligament (zonule of Zinn), whose fibres are composed of the protein fibrillin*
- *The zonule attaches the equator of the lens to the ciliary body.*
- *Disease may affect the structure, shape & position of the lens.*

CONT.

- *The accommodative (dioptric) power varies with age, being:*
  - *14 – 16 D (at birth)*
  - *7 – 8 D (at 25 years of age)*
  - *1 – 2 D (at 50 years of age)*
- *The lens grows in size continuously throughout life.*
- *The lens is composed of 64% water, 35% protein & 1% lipid, CHO & trace elements*
- *Metabolism: anaerobic*
  - *Glycolysis is responsible for 785% glucose utilization → lactate formation*
- *The refractive index → 1.39; Diameter: 9 – 10 mm; Thickness → 4mm*

STRUCTURE OF THE LENS

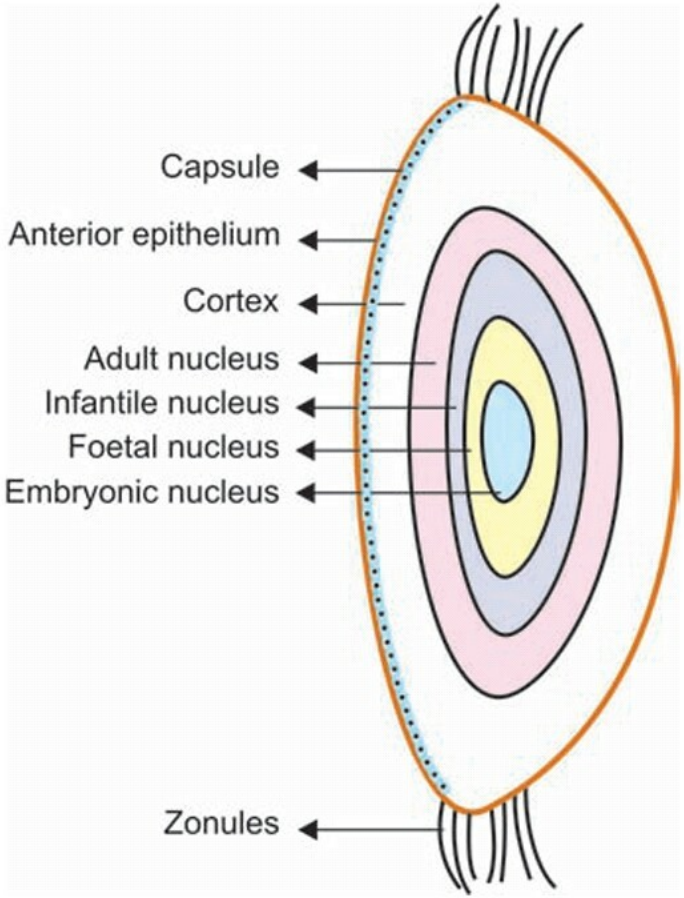

Major components of adult lens

FUNCTIONS OF LENS

- *Provides refractive power to the optical system. It is responsible for 35% of the refracting power of the eye*
- *To provide accommodation for near vision*
- *Absorption of harmful UV light*
- *To maintain it's own clarity & transparency*

DEFINITION

- *Cataract: any light – scattering opacity that develops in the crystalline lens of the eye or in its envelope*
- *When it lies on the visual axis or is extensive → visual loss*
- *It is the leading cause (~50%) of treatable blindness in the world.*
- *Large majority occurs in older subjects as a result of cumulative exposure to environmental & other influences, such as smoking, UV radiation & elevated blood sugar levels i.e., age – related cataract*

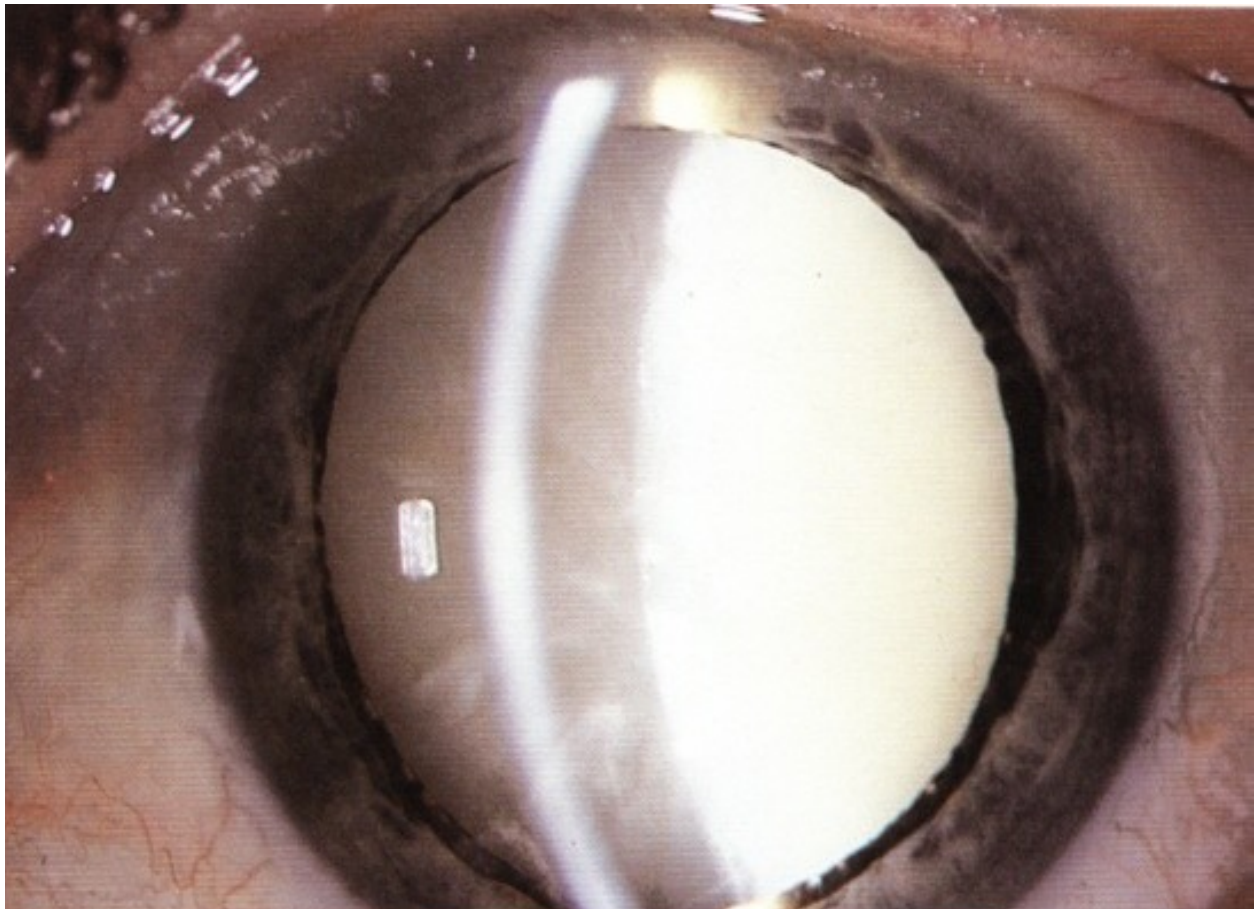

DISEASES OF THE LENS

I. CATARACT

CONGENITAL CATARACT (<1%)

1. Punctate cataract
2. Zonular cataract
3. Coronary cataract
4. Anterior capsular cataract
5. Posterior capsular cataract
6. Others → coralliform, discoid, axial, sutural cataract

ACQUIRED CATARACT (>99%)

1. Senile – cortical & unclear cataract
2. Cataract associated with ocular diseases
3. Cataract associated with systemic diseases
4. Cataract due to radiant heat of other energy
5. Traumatic cataract

OTHER DISEASES

II. DISLOCATION & SUBLUXATION

III. CONGENITAL ABNORMALITIES

CONGENITAL ABNORMALITIES

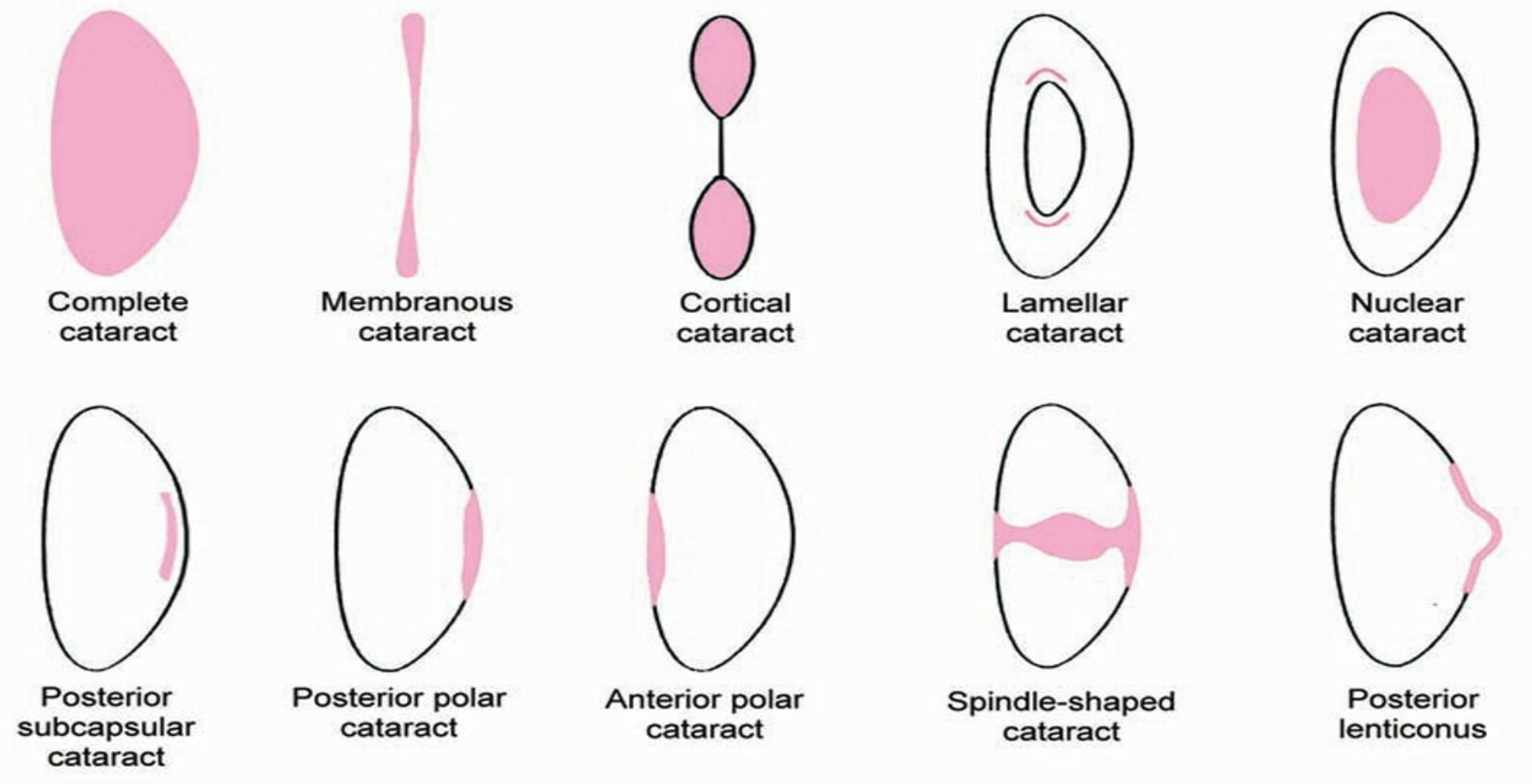

The various presentations of congenital cataract

MATURE CATARACT

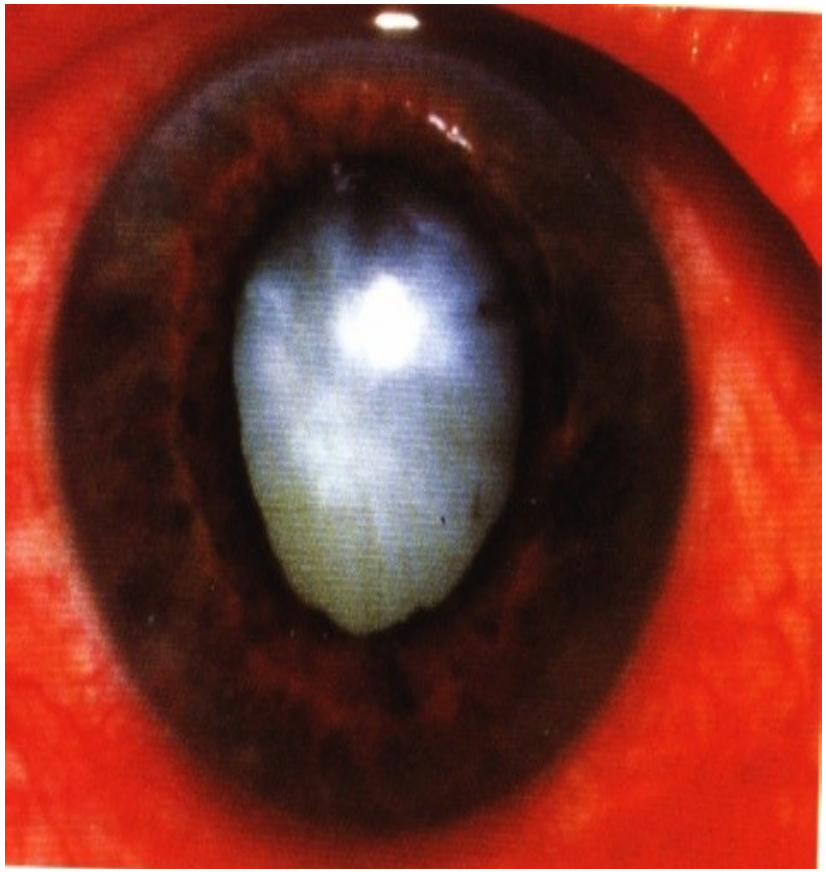

REGGE

REGGE

HYPERMATURE CATARACT

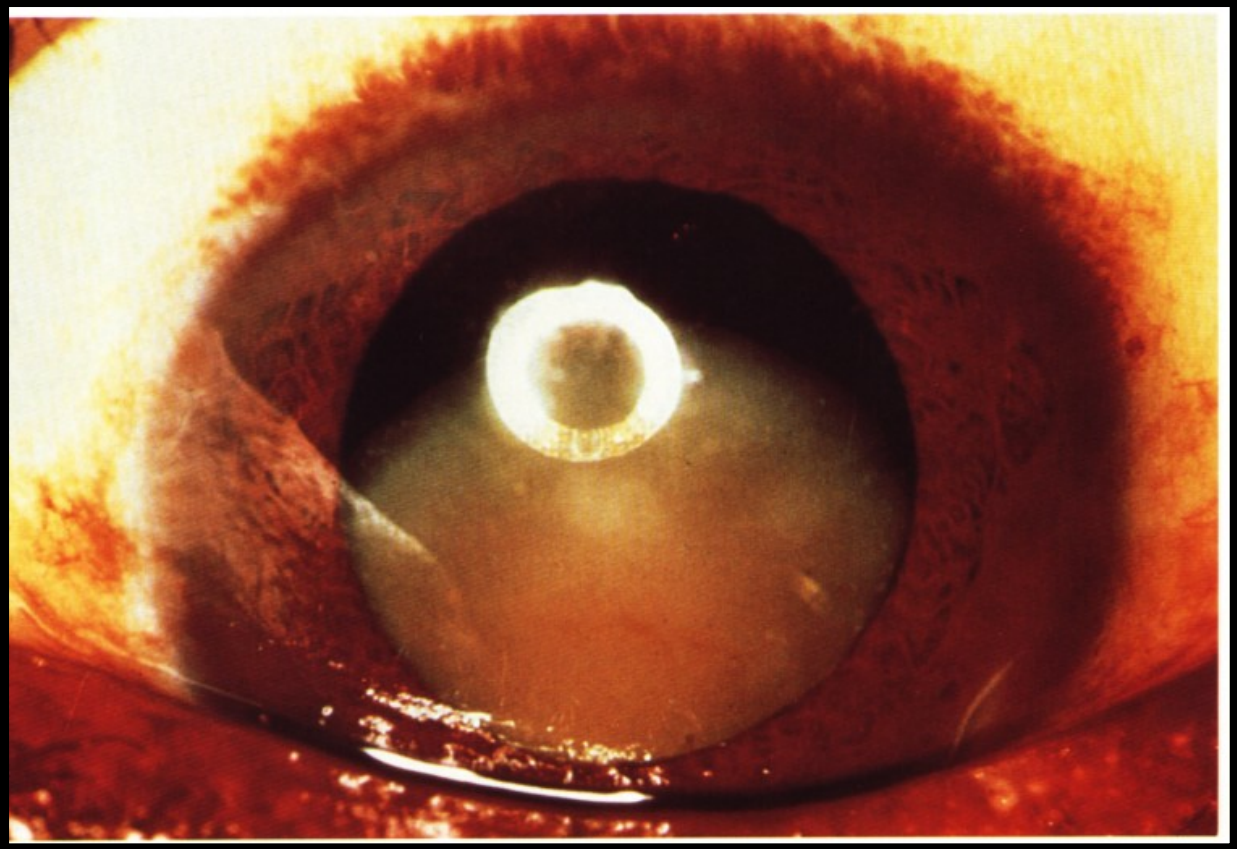

SECONDARY CATARACTS

- *Drug – induced cataracts esp. steroid eye drops*
- *Cataract 2º to:*
  - *intra – ocular inflammation e.g. chronic uveitis, iridocyclitis*
  - *High myopia*
  - *Intraocular tumor*

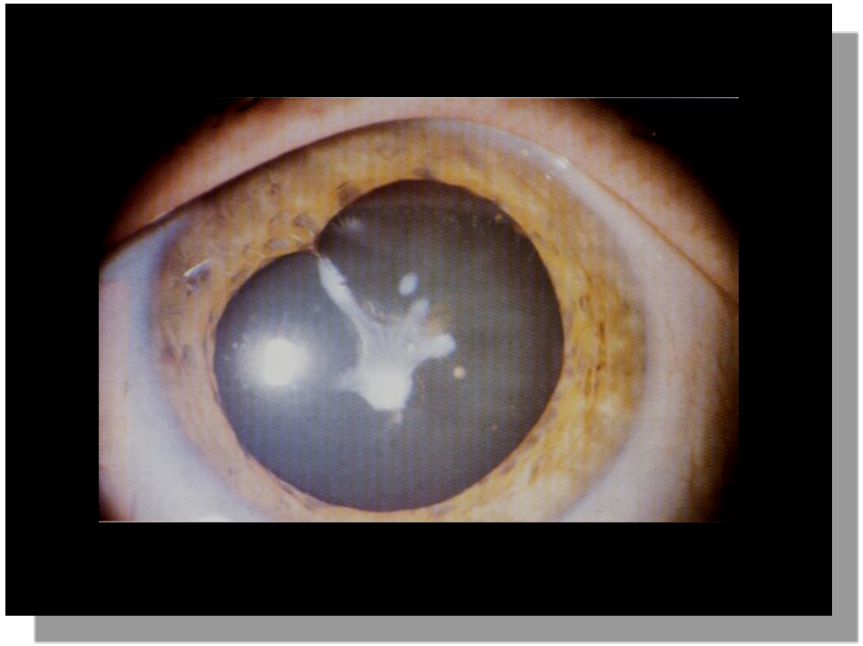

TRAUMATIC CATARACTS

- *BLUNT TRAUMA*

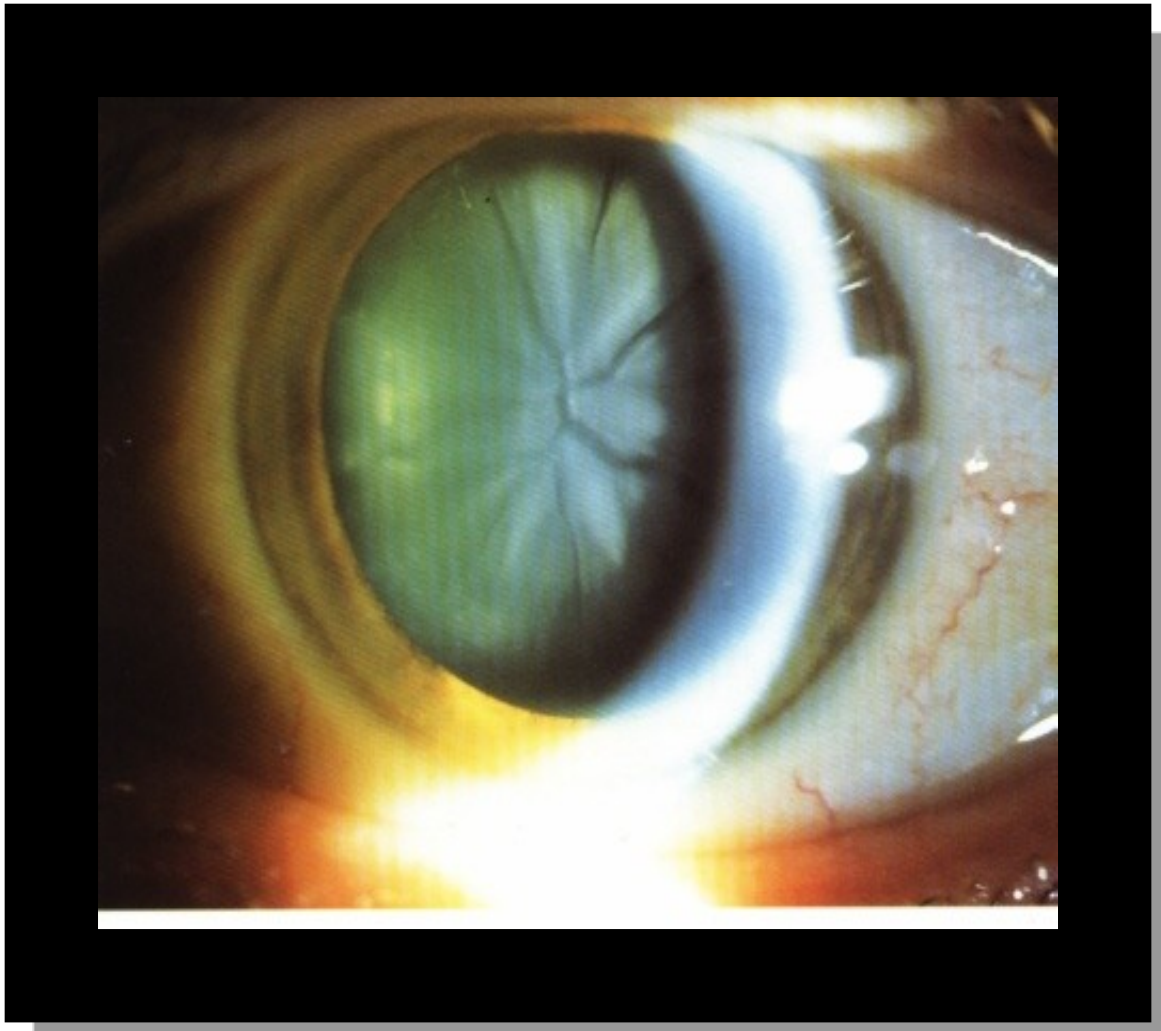

CONT.

- *Penetrating injury*
- *Surgery*

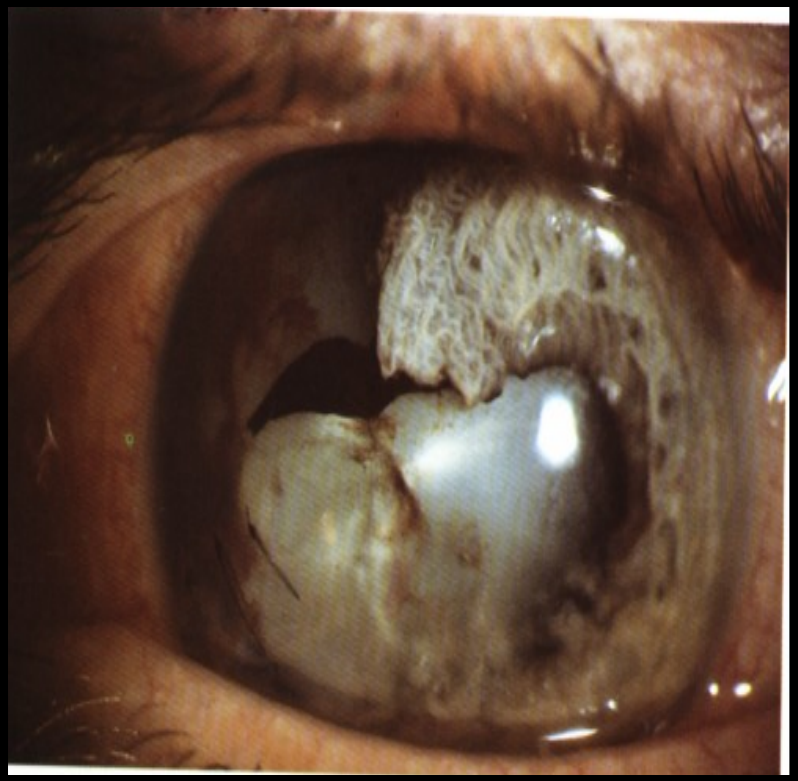

CONT.

- *Electrical injury: lightning or high voltage electric shock*
- *Radiation injuries: follow treatment with ionizing radiation e.g. X – rays, radiotherapy*

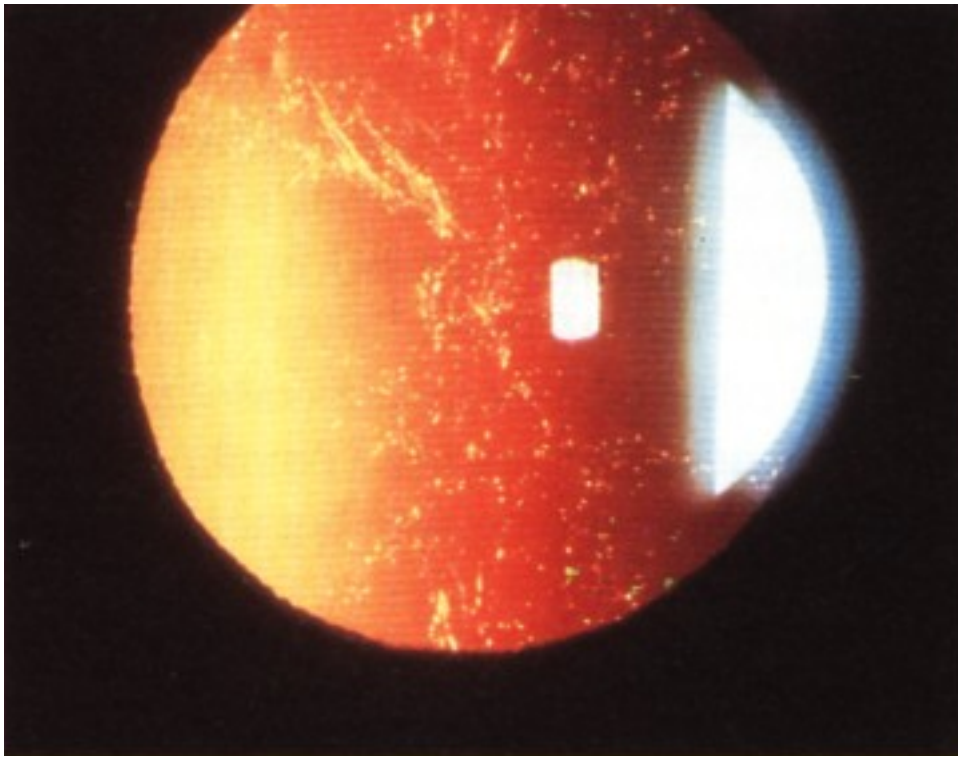

ASSOCIATION WITH SYSTEMIC CONDITIONS

- *DM*
- *Other metabolic disorders → galactosemia, hypocalcemia (parathyroid tetany), Fabry disease*
- *Systemic drugs: steroids, chlorpromazine*
- *Infection (congenital rubella)*
- *Myotonic dystrophy*
- *Atopic dermatitis*
- *Systemic syndromes (Down's, Lowe's)*
- *X - radiation*

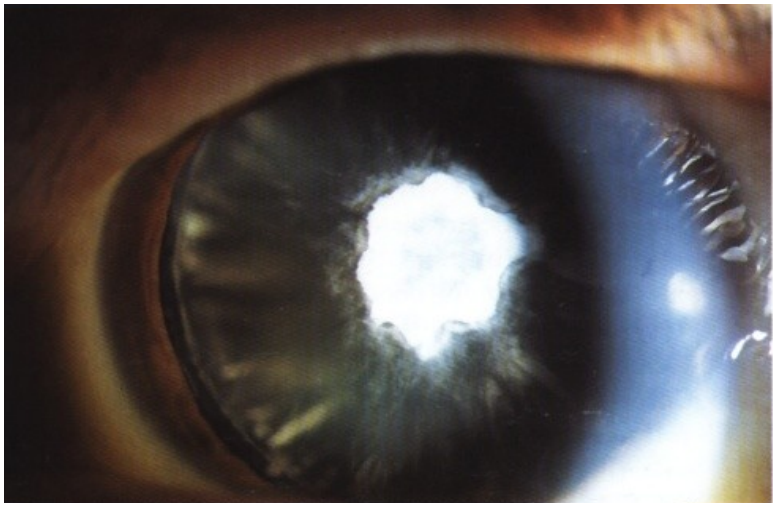

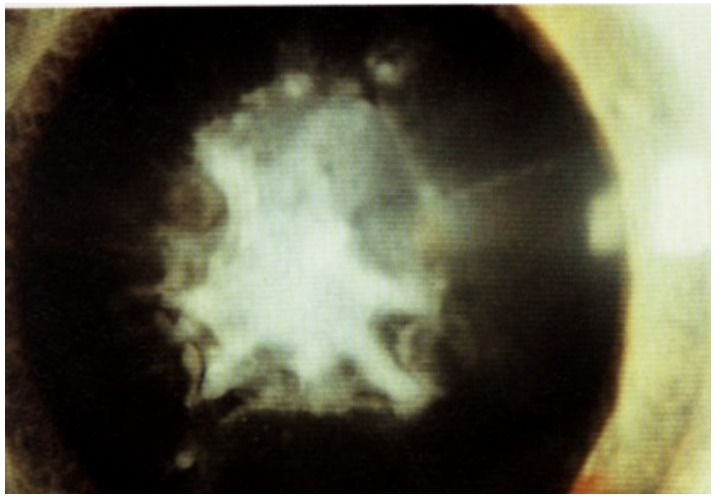

CONGENITAL CATARACTS

- *Hereditary*
- *Intrauterine infections:*
  - *Congenital rubella*
  - *Mumps*
  - *Hepatitis*
  - *Toxoplasmosis*
- *Metabolic disorders*

Congenital Rubella

COMPLICATIONS OF CATARACT: GLAUCOMA

- *Intumescent - lens absorbs water, it swells, pushes the iris forward, narrowing the angle*
- *Phacolytic - lens capsule leaks protein, blocking the trabecular meshwork*

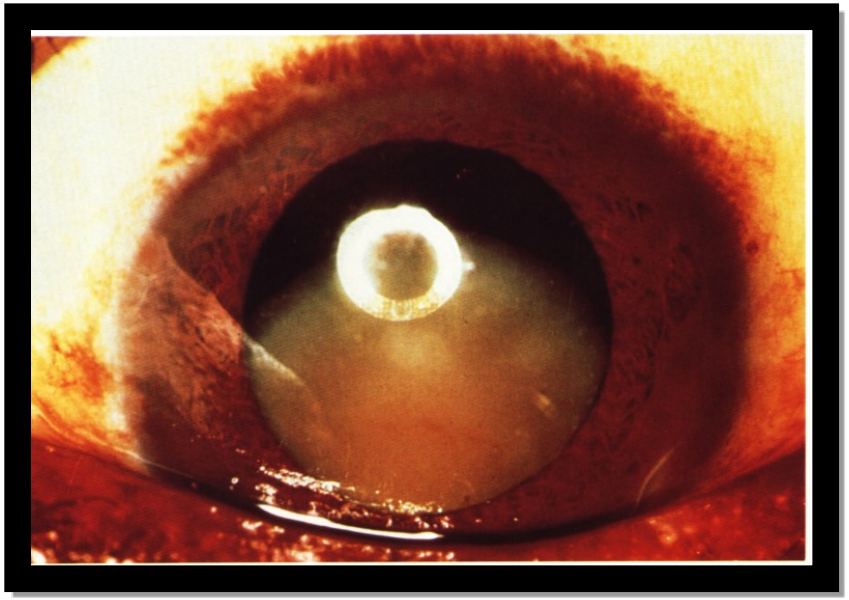

UVEITIS

- *Lens matter leaking out of the lens may cause inflammation, called phacolytic uveitis.*

SYMPTOMS

- *Painless loss of vision*
- *Glare*
- *Visible Lens Opacity*
- *Normal pupil: cataract will not affect the pupil reaction*
- *In infants, cataract causes amblyopia (a failure of visual maturation) by depriving the retina of a formed image at a critical stage of visual development.*

SIGNS

- *Gradual reduced VA: cataract alone cannot cause NPL*
- *Absent red reflex (best sign)*
- *Age – related cataract:*
  - *Commonly nuclear, cortical or subcapsular in location*
- *Slit – lamp examination:*
  - *Pigment deposition on the lens → previous inflammation*
  - *Damage to the iris → previous ocular trauma*

TREATMENT

- *No available conservative method.*
- *The only treatment is **surgical** by 2 available methods:*
  - *Intra – capsular cataract extraction (ICCE)*
  - *Extra – capsular cataract extraction (ECCE)*
- *Cataract surgery is required when the cataract is limiting daily activities*
  - *Patients may have difficulty in recognizing faces, reading, carrying out their occupation or achieving the driving standard*
  - *Some patients may be greatly troubled by glare*

CONT.

- *The operation requires access to the lens substance via an opening in the anterior part of the lens of the capsule, removal of most of the lens fibers and epithelial cells & insertion of a plastic lens implant of appropriate optical power.*
- *The implant is held in place within the capsular bag.*

PRE – OPERATIVE EVALUATION

- *Visual acuity*
- *AC depth*
- *IOP*
- *Pupil reaction*
- *Red reflex*

ICCE

- *The lens removed in one piece in an intact capsule (ICCE).*
- *This method is old and is not done.*
- *The eye is aphakic.*
- *Traditionally: couching is done*

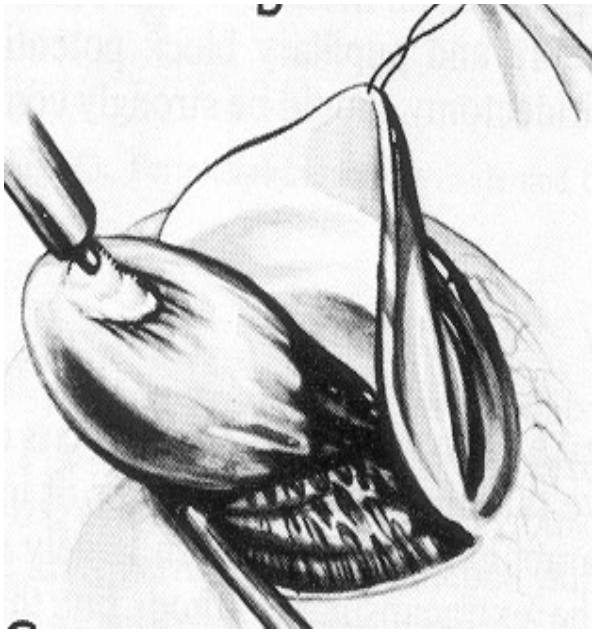

CONT.

- *Advantages:*
  - *Cheap, simple & quick*
  - *Easy to learn*
- *Disadvantages*
  - *Retinal detachment*
  - *Aphakic glaucoma*
  - *Need for aphakic glasses*
- *NB: the lens contributes to approximately 19% of the vision*

ECCE

- *The cataract is removed, leaving the posterior capsule inside the eye, usually plus an intra-ocular lens (IOL) implant.*
- *More complex, requires more equipment such as microscope, and more skilled personnel.*



CONT.

- *Advantages:*
  - *Fewer retinal complications*
  - *Allows for placement of IOL in the normal anatomic position*
- *Disadvantages*
  - *Posterior capsule, which is left behind, may become cloudy and need to be opened*

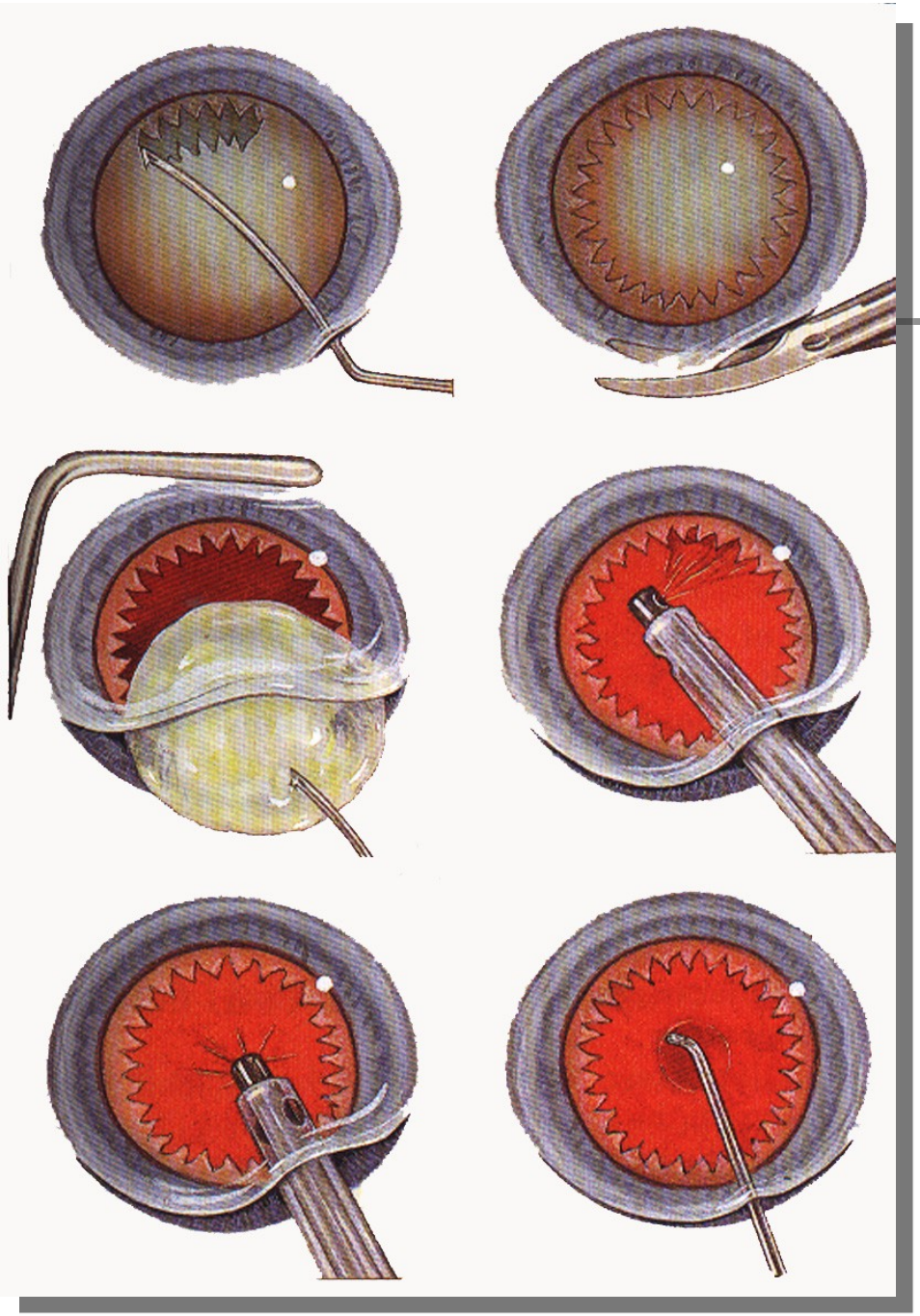



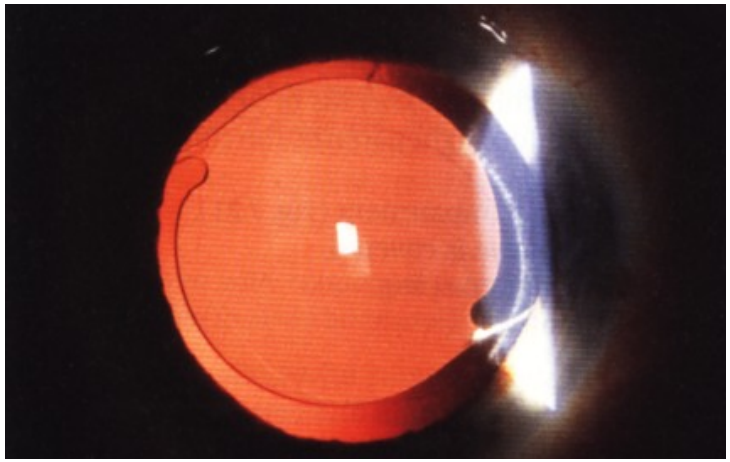

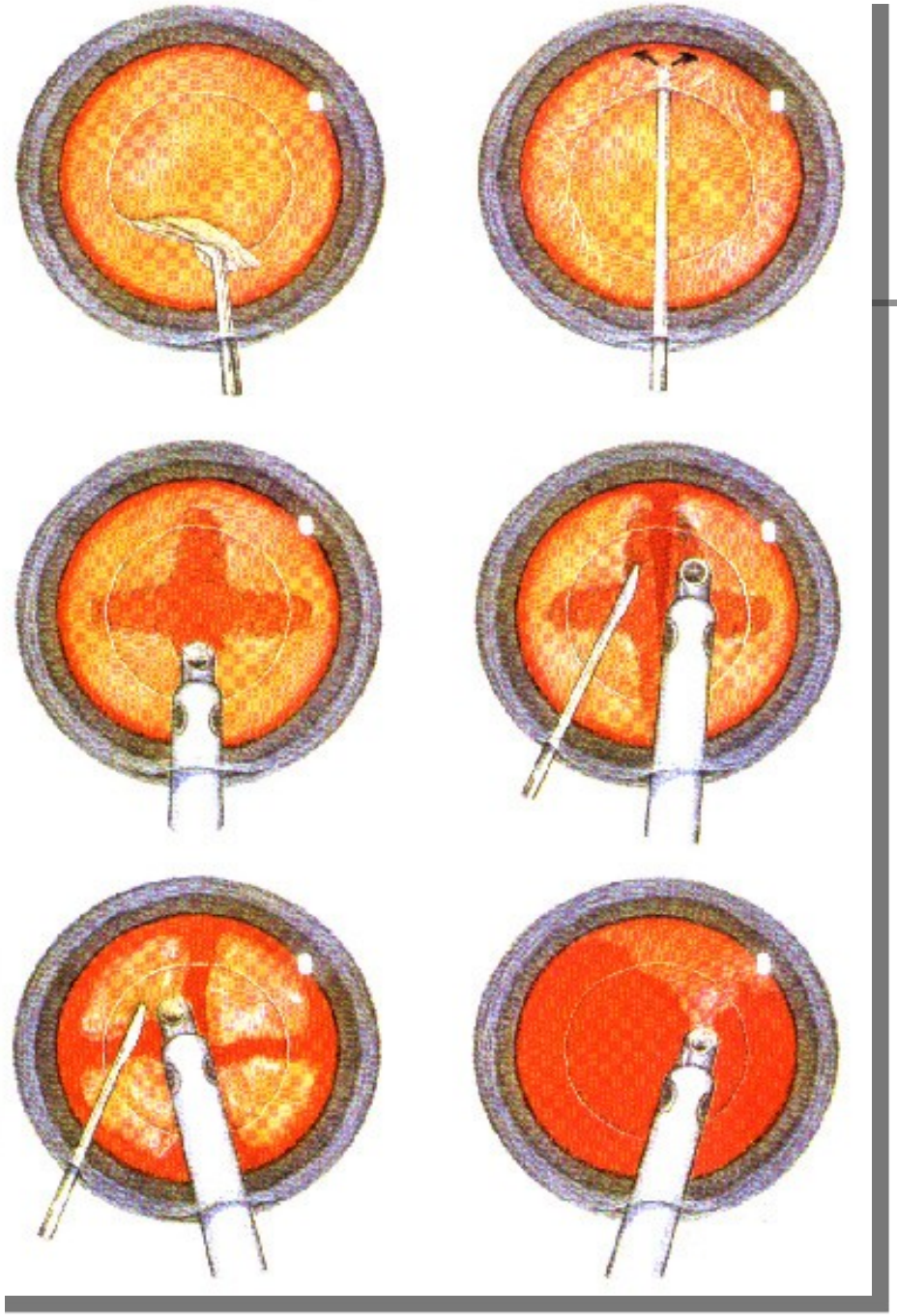

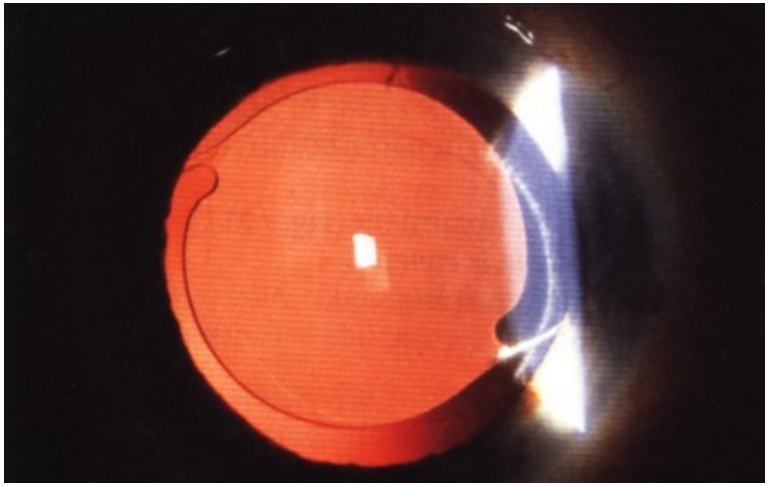

ZEISS



CORRECTION OF APHAKIA

- *Very hyperopic, or long-sighted*
- *Image formed on the retina very blurred*

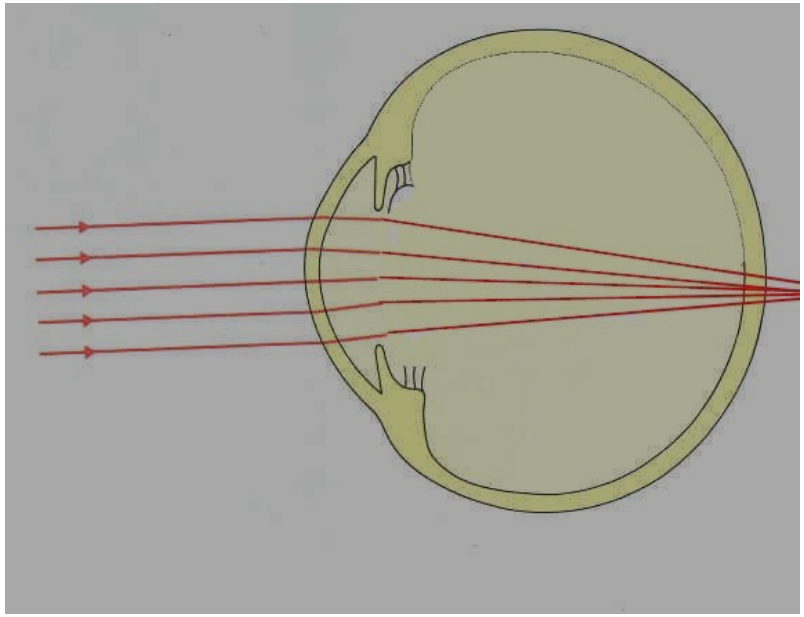

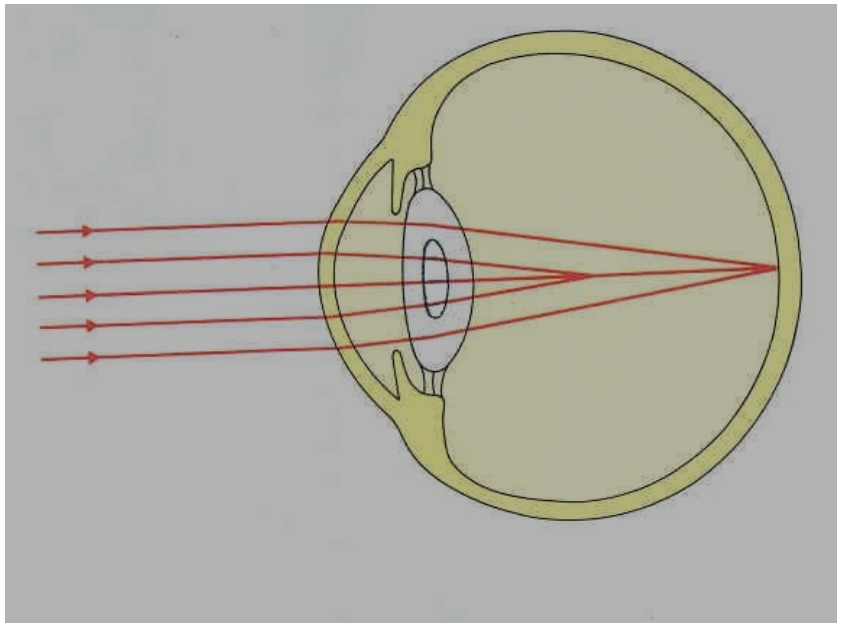

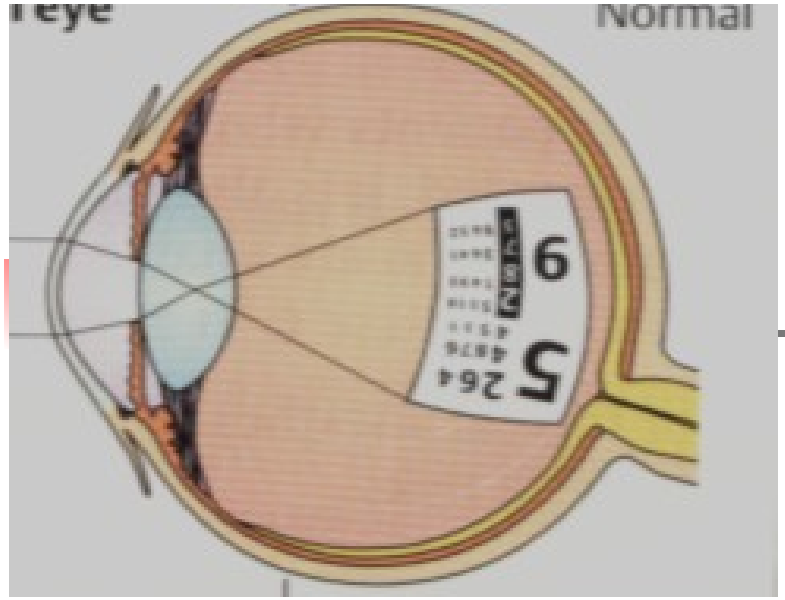
Normal

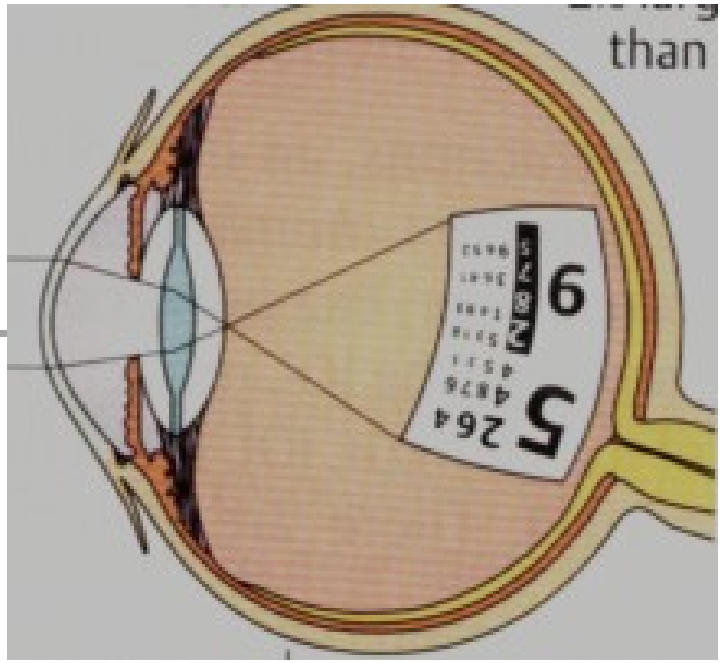
than

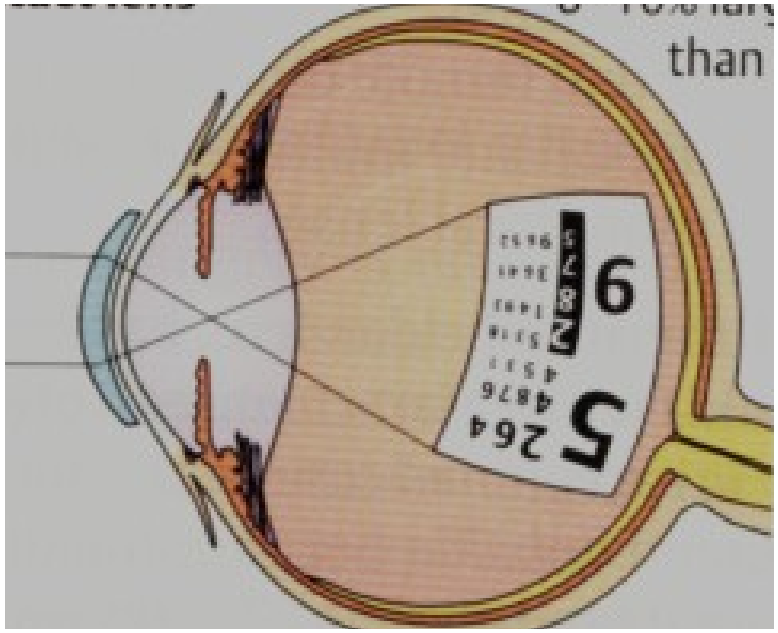
than

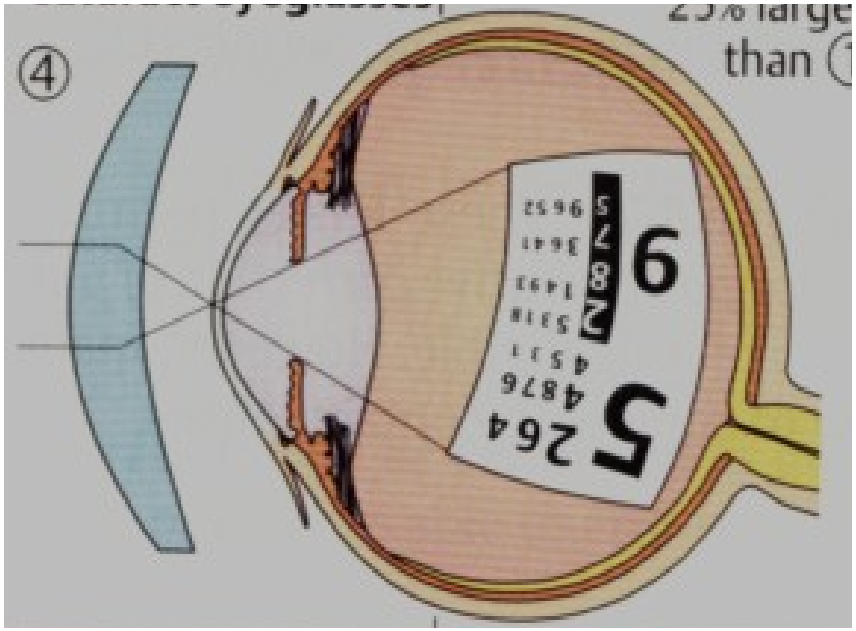
④
than

APHAKIC GLASSES

- *+10DS spectacles are inexpensive, and safe*
- *But they cause 33% magnification and distortion*
- *They are heavy and uncomfortable*
- *They can be lost or broken*
- *Jack in the box phenomenon.*

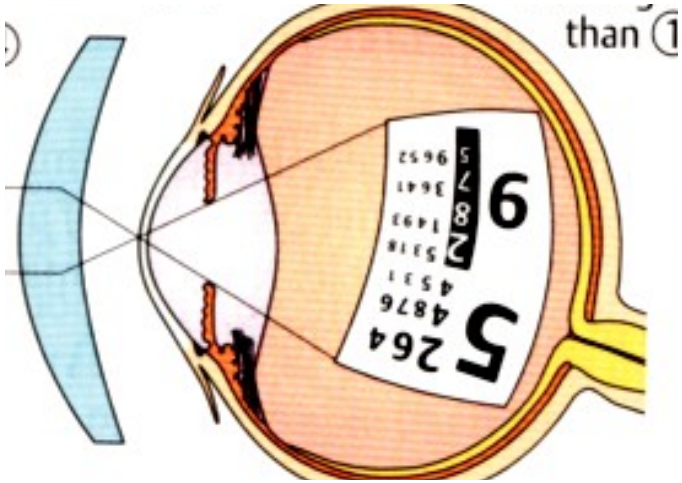

INTRA – OCULAR LENS (IOL)

- *IOLs can be placed on the posterior capsule after ECCE or in the AC after ICCE.*
- *Provide "normal" vision without glasses in over 70% of patients*
- *Cannot be lost or broken*
- *Patient unaware of their presence.*

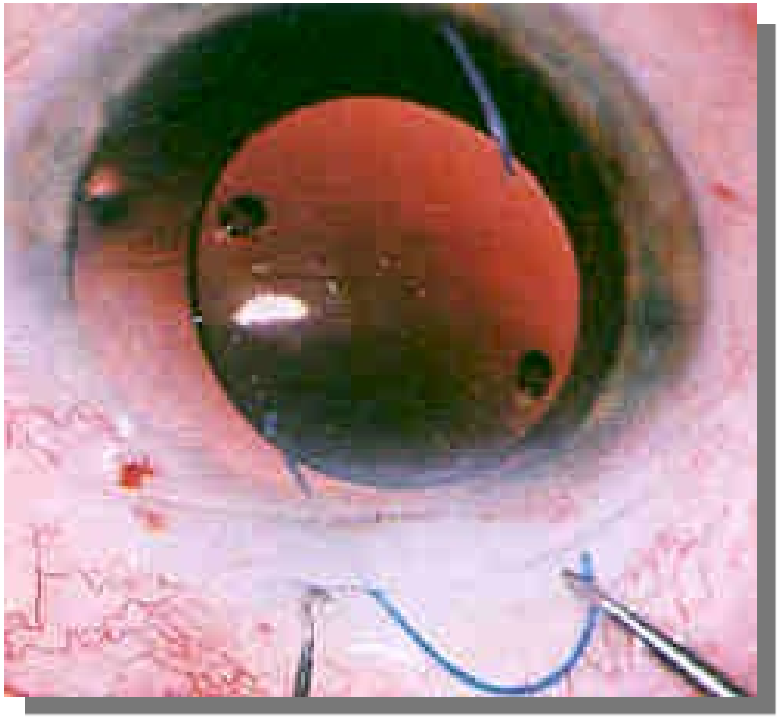

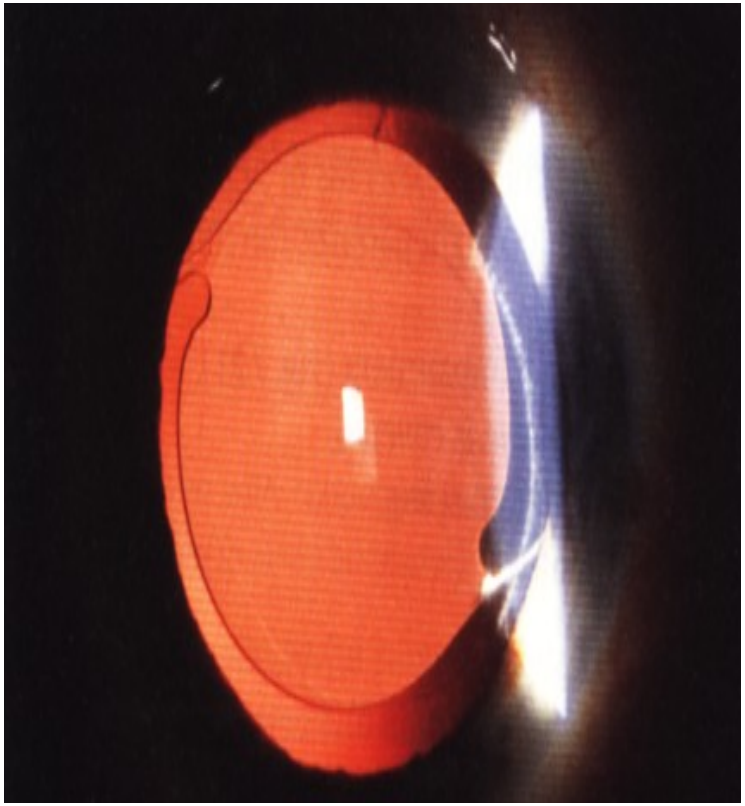

DISADVANTAGES OF IOLs

- *Not cheap.*
- *Difficult to maintain in dry, dusty environment*
- *Increase the risk of corneal ulcers and infections*

OF CATARACT SURGERY

- *They are divided into:*
  - *Intra – operative*
  - *Early post – operative*
  - *Late post - operative*

INTRA – OPERATIVE COMPLICATIONS

- *Rupture of posterior capsule*
- *Vitreous loss → following damage of the posterior capsule, the vitreous gel may come forward into the AC, where it represents a risk for glaucoma or may cause retinal traction hence necessitating vitrectomy*
- *Lens fragments in the vitreous → inflammation*
- *Expulsive Hemorrhage (very rare)*

OPERATIVE COMPLICATIONS

- *Iris prolapse: the iris may protrude through the surgical incision (dark area at incision site → pupil distortion); prompt surgical repair is required.*
- *Wound leak*
- *Striate keratopathy (endothelial damage)*
- *Acute bacterial Endophthalmitis (infection of the whole globe, rare) → remove the eye*
- *Malposition of IOL:*
  - *Tilting*
  - *Decentration*

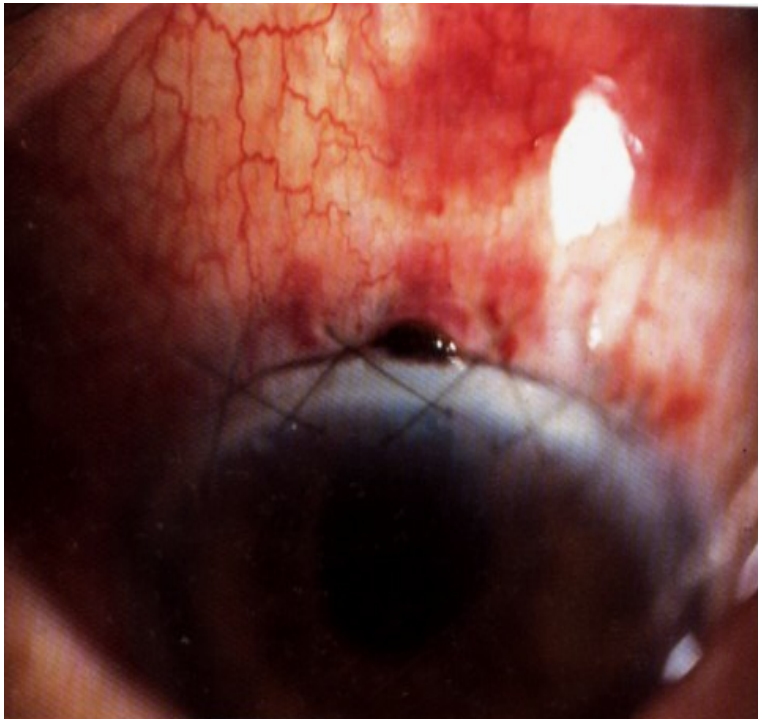

STRIATE KERATOPATHY

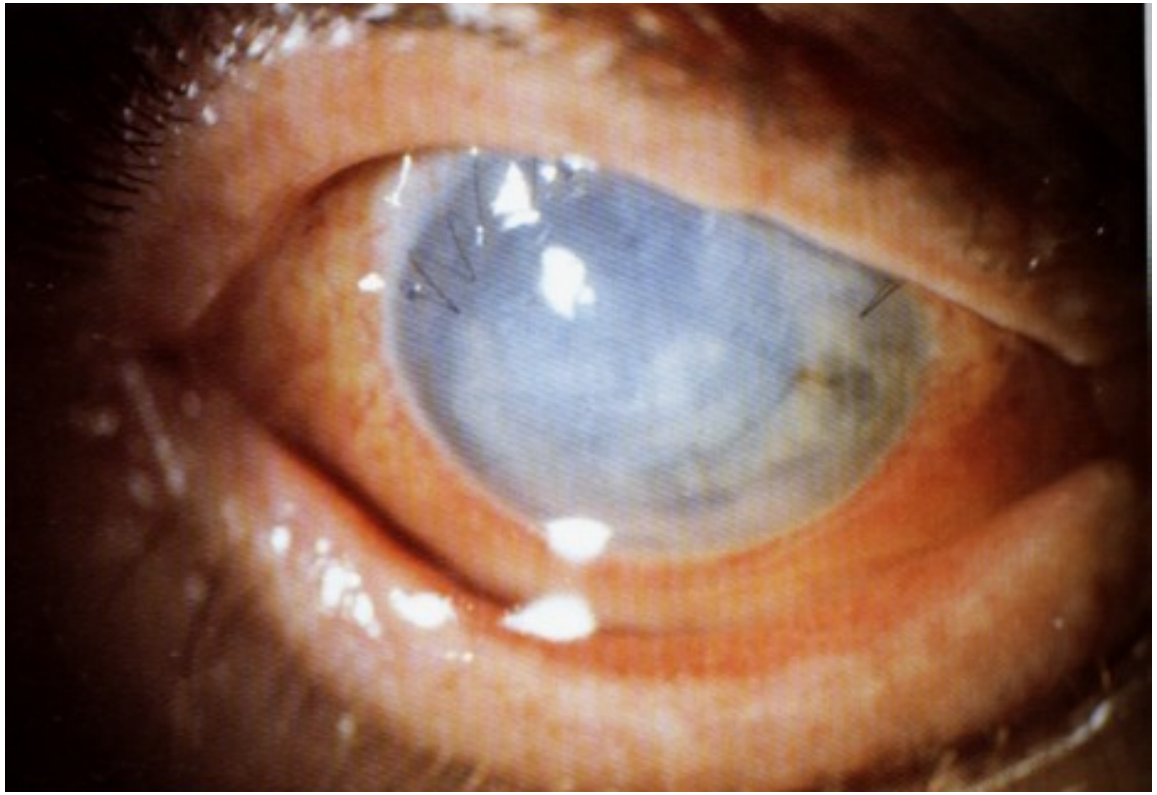

ACUTE BACTERIAL ENDOPHTHALMITIS

- *Patient presents with:*
  - *A painful red eye*
  - *Reduced VA*
  - *Hypopyon*
- *Extreme ophthalmic emergency*
- *Intra - vitreal, broad – spectrum antibiotic injection (e.g. vancomycin & ceftazidime)*

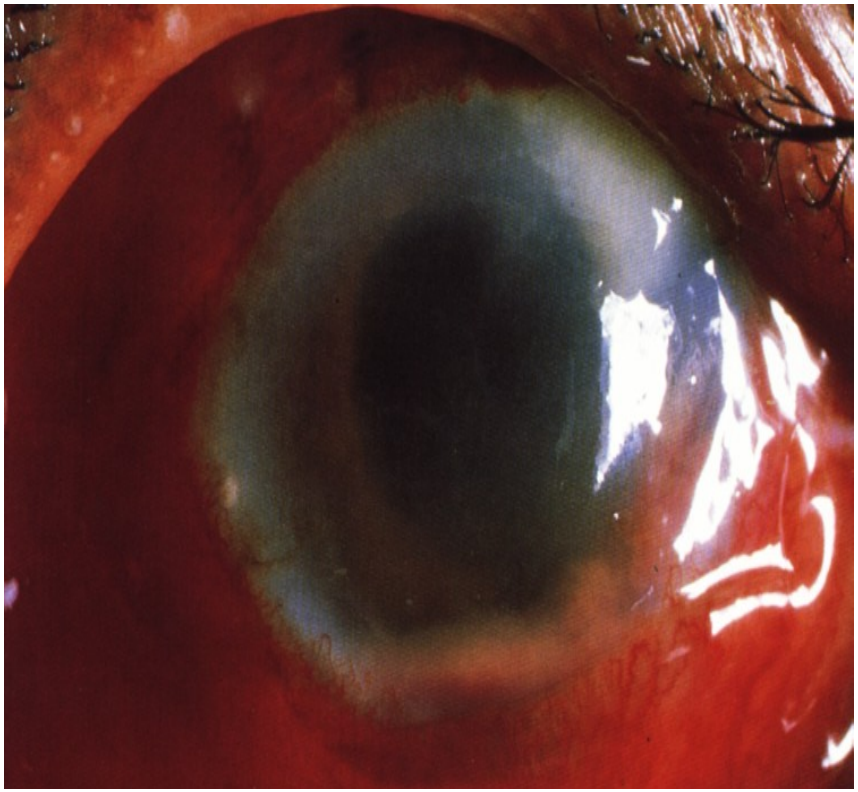

MALPOSITION OF THE IOL

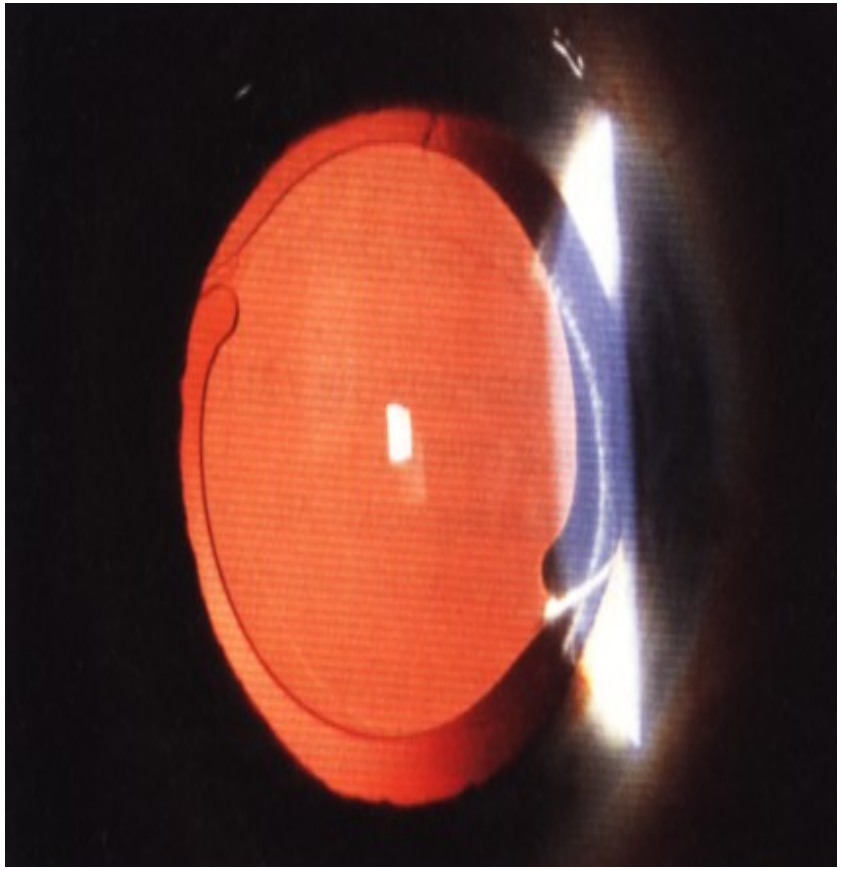

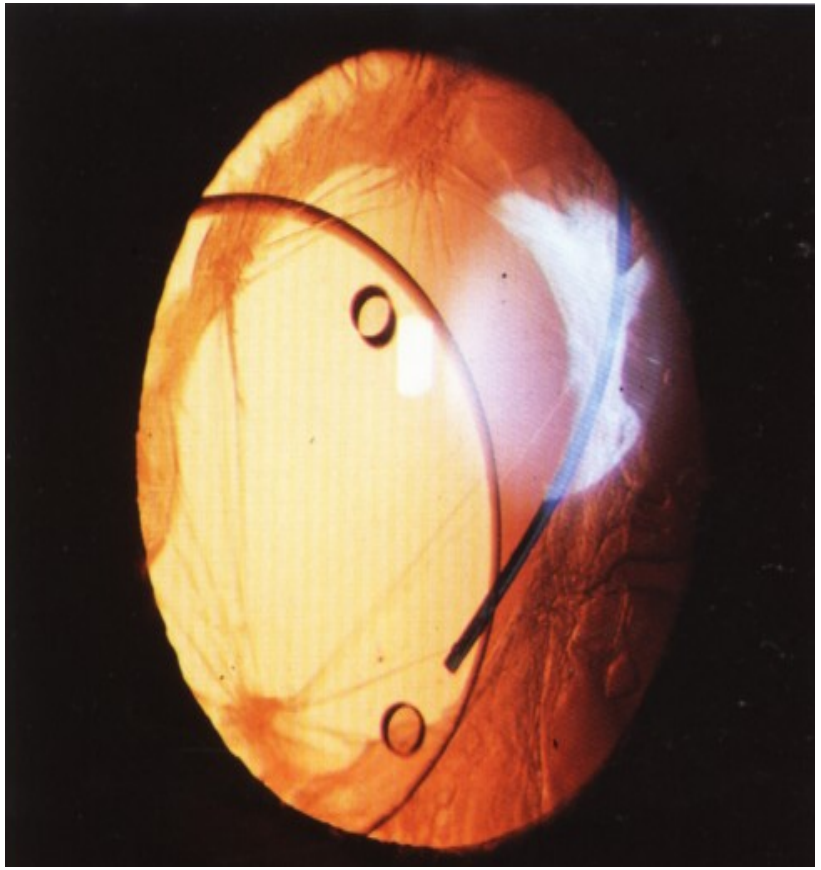

OPERATIVE COMPLICATIONS

- *Posterior capsule opacification.*
  - *Treatment: (neodymium yttrium garnet, nd YAG) Laser capsulotomy*
- *Corneal (Endothelial) de-compensation → corneal blindness → corneal graft*
- *Retinal detachment is common following:*
  - *Vitreous loss*
  - *I.C.C.E.*

POSTERIOR CAPSULE OPACIFICATION

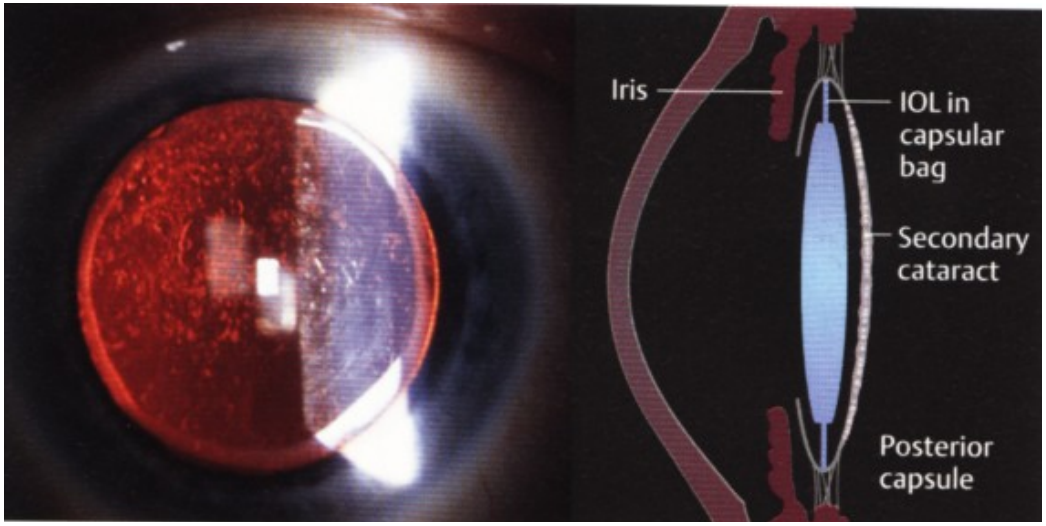

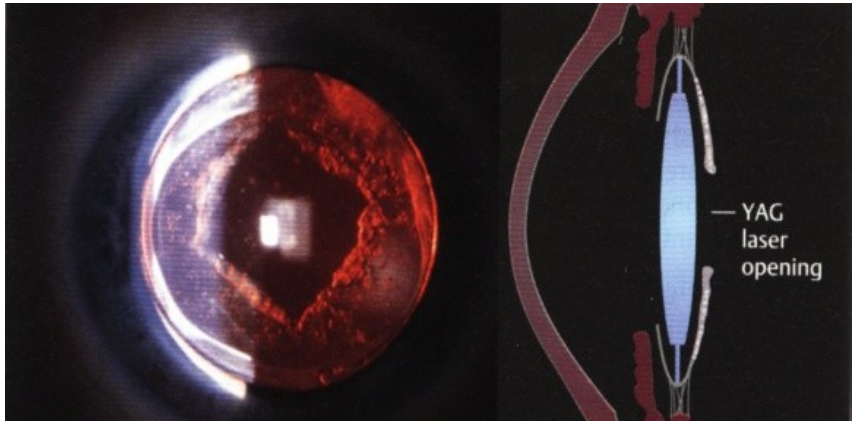

RETINAL DETACHMENT

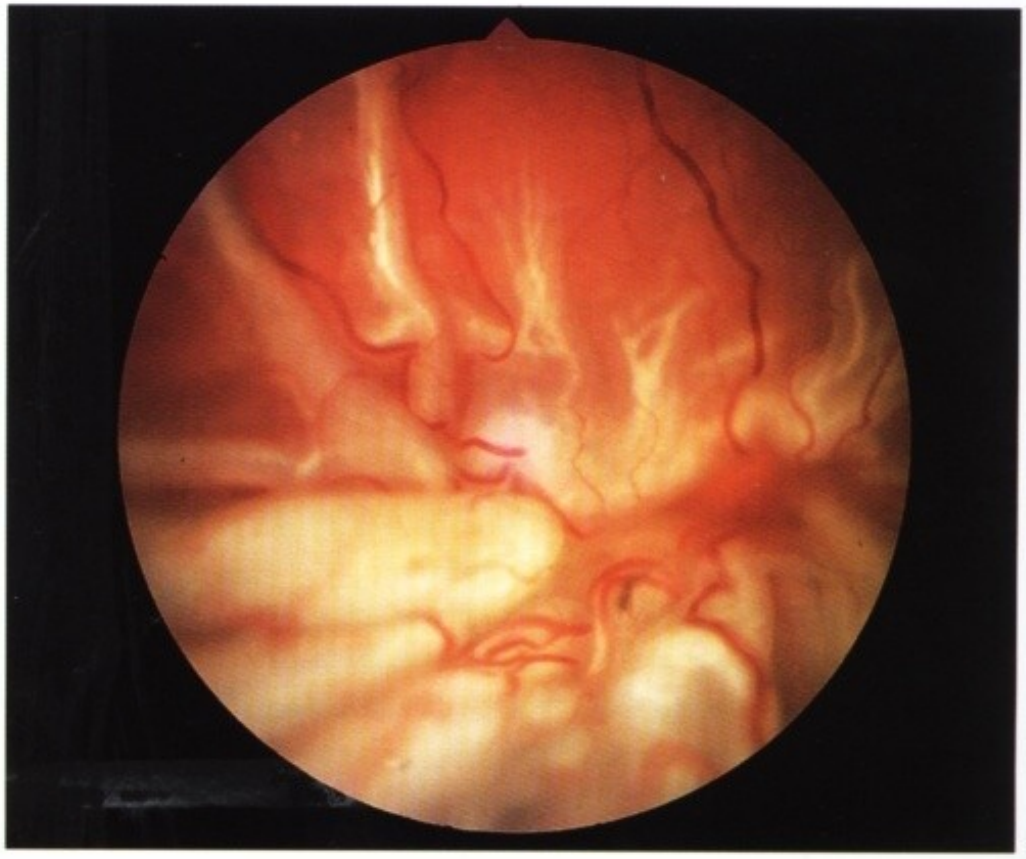

CATARACT SURGERY

- Awareness/ Advertise
- Affordable
- Accessible
- Acceptable Results
- Mobility
- Money
- Manpower
- Materials
- Management
- Marketing

PREVENTION

- *No scientifically proven prevention*
- *Wearing UV protecting sunglasses may slow the development of cataracts.*
- *Regular intake of anti-oxidants is theoretically helpful*
- *Good ante - natal care*